

# Treatment outcome of two adjacent implant crowns with different implant platform designs in the aesthetic zone: a 1-year randomized clinical trial

Nynke Tymstra<sup>1</sup>, Gerry M. Raghoobar<sup>2</sup>, Arjan Vissink<sup>1</sup>, Laurens Den Hartog<sup>1</sup>, Kees Stellingsma<sup>1</sup> and Henny J. A. Meijer<sup>1,2</sup>

<sup>1</sup>Department of Oral and Maxillofacial Surgery, University Medical Center Groningen, University of Groningen, Groningen, The Netherlands; <sup>2</sup>Department of Prosthetic Dentistry, Dental School, University Medical Center Groningen, University of Groningen, Groningen, The Netherlands

Tymstra N, Raghoobar GM, Vissink A, Den Hartog L, Stellingsma K, Meijer HJA: Treatment outcome of two adjacent implant crowns with different implant platform designs in the aesthetic zone: a 1-year randomized clinical trial. *J Clin Periodontol* 2011; 38: 74–85. doi: 10.1111/j.1600-051X.2010.01638.x

## Abstract

**Aim:** To evaluate the peri-implant tissues in patients with two adjacent implant crowns in the aesthetic zone, treated with either two adjacent implants with a scalloped platform or with a flat platform.

**Material and methods:** Forty patients were randomly allocated to: (1) a "scalloped implant group": 20 patients treated with two adjacent implants with a scalloped platform, and (2) a "flat implant group": 20 patients treated with two adjacent implants with a flat platform. Clinical and radiographic examinations were performed during a 1-year follow-up period to assess hard and soft tissue changes.

**Results:** The scalloped implant group showed significantly more marginal bone loss (scalloped:  $2.7 \pm 1.4$  mm, flat:  $0.9 \pm 0.8$  mm) and more inter-implant bone crest loss (scalloped:  $1.8 \pm 1.4$ , flat:  $1.0 \pm 0.9$  mm) than the flat implant group. There was no significant difference between the groups with regard to the papilla index and patients' satisfaction.

**Conclusion:** After 1 year of function, there was more bone loss around scalloped implants than around flat implants. With regard to the presence of papilla, there were no differences between the groups. With both applied implant designs, it is difficult to establish a predictable and harmonious aesthetic result, especially regarding the peri-implant mucosa. Patients were very satisfied with the aesthetic outcome of the adjacent implants irrespective of the treatment concept applied.

**Key words:** adjacent implants; aesthetics; clinical trial; dental implants; patient satisfaction; prospective

Accepted for publication 5 October 2010.

During the last few years, the focus in implantology has shifted from implant survival to aesthetic success. The criteria for implant success in the aesthetic

zone include the establishment of a soft tissue contour with an intact interproximal papilla and a gingival outline that is harmonious with the gingival silhouette of the adjacent healthy dentition (Choquet et al. 2001). Despite the abundance of surgical techniques available currently, the creation of a predictable papilla approximal of a single-tooth implant and especially between two adjacent implants in particular remains a complex challenge (den Hartog et al. 2008, Kourkounta et al. 2009).

Whether interproximal papillae will develop next to single tooth implants is predominantly dependent on the level of the marginal bone and the attachment level of the neighbouring teeth (Grander 2000, Kan et al. 2003). This also explains why the creation of a papilla between adjacent implants is even more of a challenge as unlike approximal of single-tooth implants, an inter-implant papilla between implants is not supported by the marginal bone level of a neighbouring tooth. In addition, the

## Conflict of interest and sources of funding

The authors declare that they have no conflict of interests.

The study has been partially funded by Nobel Biocare AB (Göteborg, Sweden) grant #2004-288.

bone condition in many such cases is also compromised. Among others, because of the traumatic loss of the teeth and/or the ongoing resorption of this area, the characteristic interdental bone peak is usually missing. In addition, it is not uncommon that significant deficiencies of the horizontal or vertical hard tissues are present in this area and are in need of an augmentation procedure to allow for reliable implant placement at a location favourable for prosthodontic rehabilitation. In other words, the placement of two adjacent implant-supported restorations in the aesthetic zone is still considered a treatment with many uncertainties whether a predictable harmonious result can be established (Tarnow et al. 2000, Kourkouta et al. 2009).

In an attempt to preserve the peri-implant hard and soft tissues and thereby make implant therapy in the aesthetic zone more predictable, several new implant designs were launched in recent years. One of these solutions is the scalloped implant, which was designed to keep or create the interproximal bony peaks that support the overlying soft tissues and thereby aiming at a preservation or the creation of papillae. The proximal scallops of the implant follow the contour of the alveolar bone crest, which is lower on the facial and oral aspects but rises in the interproximal areas. The ultimate goal of the scalloped implant design is to minimize the remodelling seen around implants, thus significantly improving the quality of survival by maintaining three-dimensional osseous and soft tissue contours (Wohrle 2003). Articles reporting on scalloped implants show contradicting results. Some studies reported that the interproximal bone crest with a scalloped implant design could be preserved (McAllister 2007, Noelken et al. 2007), whereas Kan et al. (2007) observed that bone was not regularly maintained at the original levels around the scalloped implants. Moreover, Nowzari et al. (2006) observed bone loss around the scalloped implants that was more severe than bone loss associated with properly placed flat implant designs. To date, there are no clinical prospective comparative studies in the literature, evaluating the treatment outcome of adjacent scalloped implants in the aesthetic zone.

When implants are placed in the aesthetic zone, one of the primary outcome measures should be patient satisfaction. In the end, the patient has to be satisfied with the new implant crown.

Several studies reported on patient satisfaction regarding implant crowns (Levi et al. 2003, Vermeylen et al. 2003). All these studies reported high levels of patient satisfaction. However, if the professionals' opinion was also evaluated, it was always less positive than the patients' opinion (Chang et al. 1999a, Palmer et al. 2007). Furthermore, there is a difference between patients and professionals regarding which factors are considered to be of decisive importance for a good aesthetic outcome (Chang et al. 1999b, Meijndert et al. 2007a). As such, it is important to assess the overall satisfaction of the patient along with the evaluation of the peri-implant hard and soft tissues.

Therefore, the aim of this comparative randomized clinical trial was to assess the clinical and radiographic parameters in patients with two adjacent implant crowns in the maxillary aesthetic zone, treated with either two adjacent implants with a scalloped platform (test group) or with a flat platform (control group).

## Material and methods

### Patient selection

The patients selected for this study had been referred to the Department of Oral and Maxillofacial Surgery (University Medical Center Groningen, University of Groningen, Groningen, the Netherlands) for implant-based prosthodontic rehabilitation of two adjacent anterior maxillary teeth. All patients were 18 years or older and were included in the study only after providing informed consent. The study was approved by the medical ethical committee of the University Medical Center Groningen. Patients were selected on the basis of the following inclusion criteria:

- missing or lost teeth were an incisor (central or lateral), a canine or a first premolar in the maxilla;
- teeth missing were adjacent;
- healed site (at least 3 months after tooth removal);
- sufficient bone was available for the placement of two adjacent dental implants (if required, a bone augmentation procedure was performed at least 4 months before implant placement);
- sufficient space in the mesio-distal dimensions was available for the placement of two adjacent dental

implants (with the minimum dimensions of 10 × 3.5 mm) with an inter-implant distance of 3 mm and a tooth-implant distance of at least 1.5 mm;

- sufficient space in the mesio-distal, bucco-lingual, and interocclusal dimensions was available for the placement of two functional implant crowns with an anatomical design;
- implant site was free from infection.

Exclusion criteria for this study were as follows:

- presence of medical and general contraindications for the surgical procedures;
- presence of an active and uncontrolled periodontal disease;
- bruxism;
- smoking;
- a history of local radiotherapy to the head and neck region.

The experimental design of the study was a comparative randomized clinical trial.

### Surgical and prosthetic procedure

To rehabilitate the missing adjacent teeth, two treatment modalities were applied: (1) the 'scalloped implant group' (test group), consisting of 20 patients treated with two adjacent implants with a scalloped implant platform (NobelPerfect Groovy; Nobel Biocare AB, Göteborg, Sweden), and (2) the 'flat implant group' (control group), consisting of 20 patients treated with two adjacent implants with a flat implant platform (NobelReplace Groovy; Nobel Biocare AB) (Fig. 1). When deemed necessary, large recontouring and overcontouring has been carried out in a separate session to require a 2–3-mm-thick bone wall on the facial aspect of the implants. Randomization by minimization (Altman 1991) was used to balance the possible prognostic variables between the treatment groups. Minimization was used for the location of the implant site (two central incisors, central and lateral incisor, lateral incisor and canine or canine and first premolar) and whether or not a pre-implant augmentation procedure was indicated based on a clinical and diagnostic cast assessment. Both types of implants used in this study were tapered and moderately roughened to the top of the

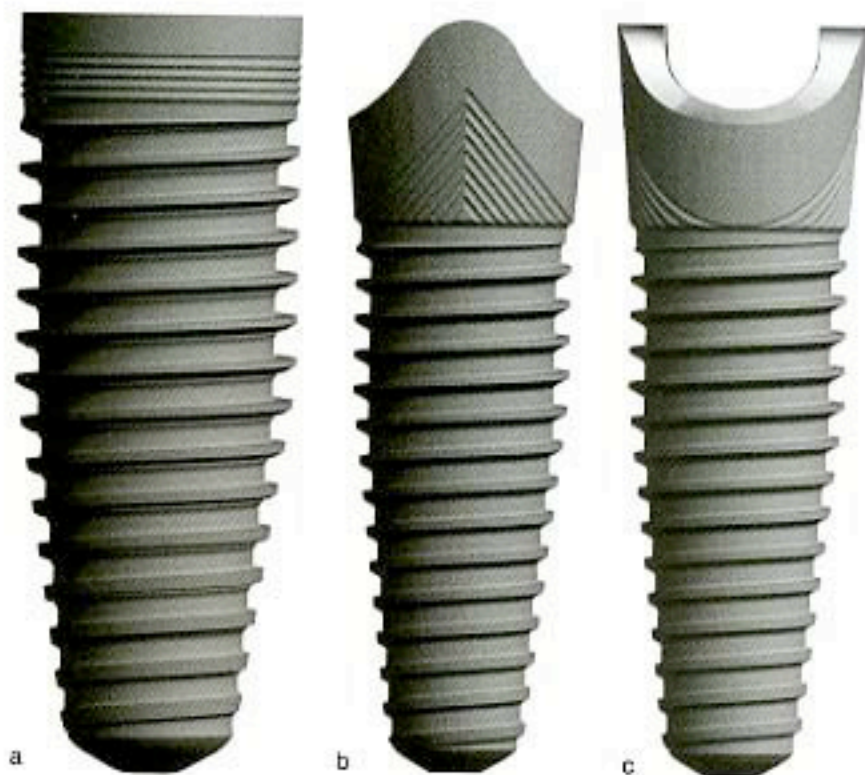


Fig. 1. Illustration of the (a) flat implant design and (b) the scalloped implant design from a proximal and (c) a buccal point of view.

implants with a titanium oxide (TiUnite; Nobel Biocare AB).

All patients were treated in the same department (Oral and Maxillofacial Surgery, University Medical Center Groningen, University of Groningen, Groningen, the Netherlands) by one experienced oral-maxillofacial surgeon and two experienced prosthodontists. Pre-operatively, diagnostic casts were made with a diagnostic arrangement representing the future implant crown in the ideal prosthetic position. Next, this ideal crown position was translated into a surgical template by fabricating a transparent acrylic resin template (Vertex Castpress; Vertex-Dental BV, Zeist, the Netherlands). The surgical guide was completed with a guide channel, which was prepared in the template to aid proper implant placement. The surgical template was tooth supported and mimicked the desired emergence profile of the future implant crown.

One day before implant placement, the patients began using a 0.2% chlorhexidine mouthwash (Corsodyl; GlaxoSmithKline, Utrecht, the Netherlands). One day before implant surgery, patients started taking antibiotics (amoxicillin 500 mg, three times daily

for 7 days or clindamycin 300 mg, four times daily for 7 days in case of amoxicillin allergy) and using a 0.2% chlorhexidine mouthwash (two times daily for 7 days) for oral disinfection. Under local anaesthesia (Ultracaine D-S Forte; Aventis Pharma Deutschland GmbH, Frankfurt, Germany), the implants were placed, according to the manufacturer's instructions, guided by the surgical template. A mucoperiosteal full-thickness flap was raised, which provided a clear view of the (availability and quality of the) hard tissues of the surgery area. In the coronal-apical position, the facial parts of the platforms of both implant designs were placed 2–3 mm apical to the most apical portion of the surgical template. The implants were placed with a maximum of 45 N cm torque. In the 'scalloped implant group', the interproximal peaks of the implants were aligned towards the interproximal bone, facing the adjacent teeth or the adjacent implants. Alignment of the interproximal peaks of the adjacent implants followed the natural arch curvature instead of a straight line. The final rotational alignment of the scalloped implants was achieved using the manual torque wrench (Nobel Bio-

care AB). Furthermore, when the bone apposition area of the implants remained uncovered after proper positioning in the coronal-apical direction, a local augmentation was performed. For this small simultaneous augmentation procedure, an autogenous bone graft, collected during drilling (bone collected from the grooves of the bur) or harvested intra-orally, was combined with anorganic bovine bone (spongiosa granules, 0.25–1.0 mm, Geistlich Bio-Oss<sup>®</sup>; Geistlich Pharma AG, Wolhusen, Switzerland) and overlaid with a Geistlich Bio-Gide<sup>®</sup> resorbable bilayer membrane (Geistlich Bio-Gide<sup>®</sup>; Geistlich Pharma AG). The wound was closed primarily with sutures (Ethilon 5-0; Johnson & Johnson Health Care, Piscataway, NJ, USA). For pain control, 600 mg ibuprofen (Brufen Bruis 600; Abott BV, Hoofddorp, the Netherlands) was prescribed, to be taken three times daily if needed. Two weeks following implant surgery, the sutures were removed.

Three months after implant placement, the implants were uncovered and a healing abutment (Scalloped implant group; NobelPerfect healing abutment and flat implant group; NobelReplace healing abutment, Nobel Biocare AB) was placed.

Two weeks later, an open tray impression was made at the implant level using a custom acrylic resin impression tray (Lightplast base plates; Dreve Dentamid GmbH, Unna, Germany) and a polyether impression material (Impregum Pentix; 3M ESPE, St. Paul, MN, USA). In the dental laboratory, screw-retained provisional crowns were fabricated, consisting of a temporary abutment ('scalloped implant group'; temporary abutment titanium NobelPerfect or the 'flat implant group'; NobelReplace temporary abutment Engaging; Nobel Biocare AB), against which a veneering composite (Solidex; Shofu Inc., Kyoto, Japan) was modelled. One week after the impression was made, the healing abutments were removed and the provisional crowns were placed and torqued to 32 N cm. The provisional crowns were contoured so that the peri-implant soft tissue was optimally supported. Extra care was given to the interproximal areas; the interproximal papillae were given enough space to regenerate. For 3 months, the patients visited the prosthodontist once per month for examination. The most important objective during these appointments was the creation of

an ideal emergence profile of the provisional crowns. When needed, the crowns were unscrewed and adjusted by removing or adding composite resin to create more space or more support for the peri-implant soft tissues.

Three months later (6 months following implant placement, 3 months after abutment connection), another implant-level impression was made for the fabrication of the definitive crown. In the dental laboratory, a soft tissue cast was prepared. First, a waxing of the definitive crowns was made on temporary abutments ("scalloped implant group"; temporary abutment titanium NobelPerfect or "flat implant group"; NobelReplace Temporary Abutment Engaging; Nobel Biocare AB). After that, the waxing was cut back to the desired form and scanned for the fabrication of individual zirconia abutments (Procera; Nobel Biocare AB). As there were no individual zirconia abutments available for the NobelPerfect implants, an individual titanium abutment was fabricated, covered by a zirconia coping (Procera; Nobel Biocare AB). If the screw access hole was located mid-palatinally, the porcelain was added directly to the abutment to create a screw-retained crown. The crowns were placed and the abutment screws were torqued to 32 Ncm. Finally, the screw holes were filled with a cotton pellet and composite resin (clearfil AP-X; Kuraray Medical Inc., Okayama, Japan). If the access hole was not located mid-palatinally, a full ceramic zirconia crown was fabricated separately. The screw-retained abutments were torqued to 32 Ncm and the crown was fastened on the abutment with glassionomer cement (Fuji Plus cement; GC, Alsip, IL, USA).

#### Clinical examinations

Pre-operatively ( $T_{pre}$ ), 1 month ( $T_0$ ) and 1 year ( $T_1$ ) after the placement of the definitive implant crowns, the soft tissues around the adjacent implants and their neighbouring teeth were clinically examined by one and the same examiner (N. T.) by assessing the following parameters:

- papilla index according to Jemt (1997);
- pocket probing depth: the depth of the sulcus was measured to the nearest millimetre using a manual periodontal probe (Williams Color-

Coded Probe; Hu-Friedy, Chicago, IL, USA) at three locations around the implants and the neighbouring teeth (at the side of the neighbouring teeth, midbuccally and at the side of the adjacent implants).

#### Photographic examinations

Pre-operatively ( $T_{pre}$ ), 1 month ( $T_0$ ) and 1 year ( $T_1$ ) after the placement of the definitive implant crowns, clinical standardized photographs were taken from the adjacent implant crowns and the neighbouring teeth (Meijndert et al. 2004) (Figs 2 and 3). The photographs were analysed by one and the same examiner (N. T.) using computer software to perform linear measurements on the digital photographs. The known length of a periodontal probe, which was photographed together with the dentition, was used for calibration.

The level of the marginal gingiva was assessed to the nearest 0.1 mm by measuring (1) the vertical distance from the incisal edge of the crown to the tip of the

papilla at the proximal side facing the neighbouring teeth and (2) at the proximal side facing the adjacent implants, and (3) the vertical distance from the incisal edge to the marginal border of the gingiva assessed midbuccally.

#### Radiographic examinations

Two weeks after implant placement ( $T_{post}$ ), 1 month after the placement of the definitive implant crowns ( $T_0$ ) and 1 year after placement of the definitive implant crowns ( $T_1$ ), digital periapical radiographs (Planmeca Intra X-ray unit, Planmeca, Helsinki, Finland) were taken using a paralleling technique (Figs 4 and 5). A computer-assisted calibration was carried out in the horizontal plane and, if necessary, in the vertical plane for each radiograph. In the horizontal plane, the known dimension of the diameter of the implant was used to calibrate the radiograph. When the implant was slightly angulated, the radiograph was also calibrated in the vertical plane by using the known distance of several threads as

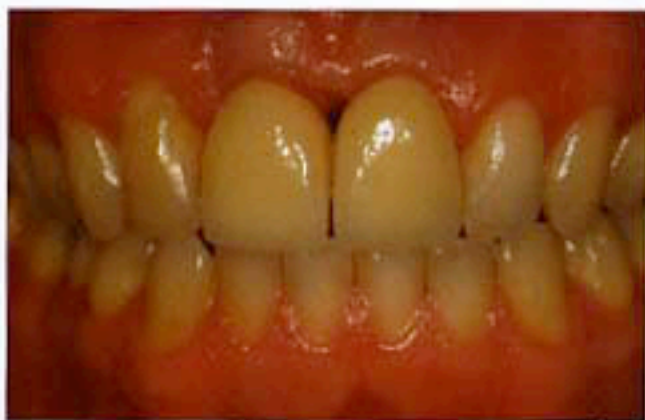

Fig. 2. Picture of a clinical situation of two adjacent scalloped implants at  $T_1$ .

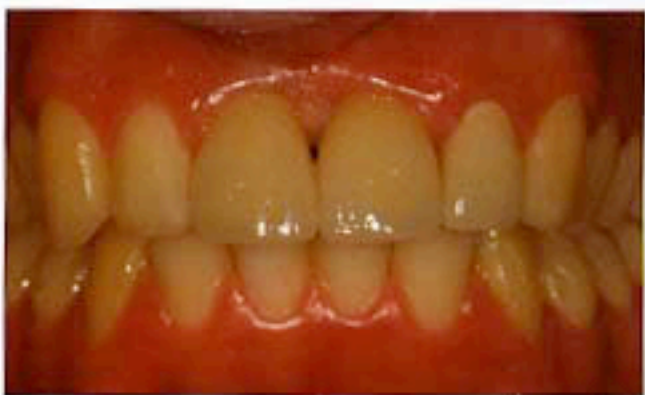

Fig. 3. Picture of a clinical situation of two adjacent flat implants at  $T_1$ .

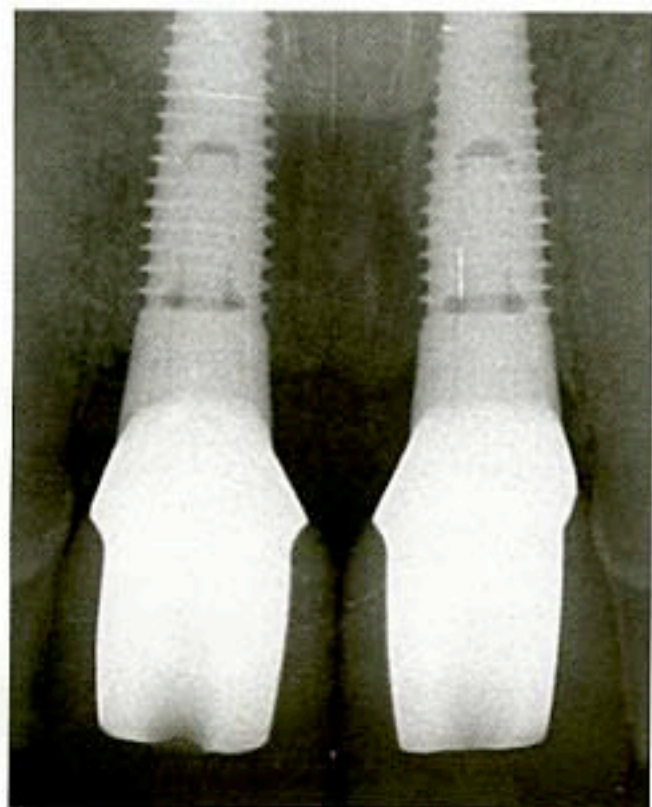


Fig. 4. Radiograph of two adjacent scalloped implants at  $T_1$ .

calibration. This calibration ensured a correct measurement (Sewerin 1990). The radiographs were analysed using specially designed computer software to perform linear measurements on the digital radiographs (in cooperation with the Department of Biomedical Engineering, University Medical Center, Groningen). Measurements were excluded if one of the landmarks to be determined could not be identified confidently. In the *vertical* plane, the following linear measurements were assessed to the nearest 0.1 mm (Fig. 6):

- For the scalloped implant group: the apical corners of the implant collar were used as a reference line (line  $a_{scd}$ ) and for the flat implant group: the interface of the implant and the abutment was used as a reference line (line  $a_{flat}$ ) from which all distances were measured;
- The first bone to implant level: the vertical distance between  $a$  and the first bone to implant level, measured at the implant side facing the adjacent implant ( $MBI_1$ ) and at the implant side facing the neighbouring tooth ( $MBI_2$ );
- The bone level of the neighbouring tooth: the vertical distance between  $a$  and the first bone to tooth level ( $MBT$ );
- The bone crest level: the vertical distance between  $a$  and the most coronal bone peak of the inter-implant bone crest ( $BC_{i-1}$ ) and the most coronal bone peak of the bone crest between the implants and their neighbouring teeth ( $BC_{i-2}$ ); and
- The incisal edge of the implant crown: the vertical distance between  $a$  and the incisal edge of the implant crowns ( $I_1$ ).

In the *horizontal* plane, the inter-implant distance: the distance between the two adjacent implants was measured at the height of the implant neck of the two adjacent implants ( $HD_{i-1}$ ).

The true marginal bone level for 'the scalloped implant group' was calculated by combining the radiographic assessments with the known dimensions of the NobelPerfect implants (Nobel Biocare AB): the actual proximal implant abutment interface was located at the top of the interproximal scallops. Therefore, the true marginal bone level was calculated as the measured first

bone to implant level plus the actual height of the scallops of the implant collar, which is 4.01 mm for the NobelPerfect regular platform implants and 3.64 mm for the NobelPerfect narrow platform implants.

All measurements were performed twice and the mean value was calculated. The error of the method used was reported to be  $0.13 \pm 0.01$  (mm) for the assessment of the radiographic marginal bone height (Meijndert et al. 2004). All radiographic assessments were performed by a single observer (N. T.).

#### Implant crown aesthetic index

Aesthetic outcome by the professional was rated using the Implant Crown Aesthetic Index as described by Meijer et al. (2005) by one and the same examiner (K. S.). In this index, nine items are judged, which have an influence on the aesthetic result. The items are based on the anatomic form, colour and surface characteristics of the restoration and on the anatomic form, colour and surface characteristics of the peri-implant soft tissues. The index was applied to both implants separately. To assess the overall score, the implant with the lowest index score was used as the score per patient.

#### Patients' satisfaction

A subjective appreciation of the final result of the treatment was carried out using a modified patient questionnaire of the one used by Meijndert et al. (2007a). The questionnaire comprised an overall satisfaction score (range: 0–10), two questions concerning the implant-supported restoration and two questions concerning the peri-implant mucosa (possible score: 0–4).

Examiners were trained and calibrated for all outcome measures. Examiners were blinded for the photographs. The radiographic examination could not be blinded, as the study group could be deduced from these radiographs.

#### Statistical analysis

Sample size was calculated using G\*power version 3.1 (Paul et al. 2009). We considered 0.5 mm of radiographic marginal bone loss from implant placement to 18 months thereafter as a relevant difference between study groups. With an expected standard deviation of 0.6 mm as derived from the literature (den

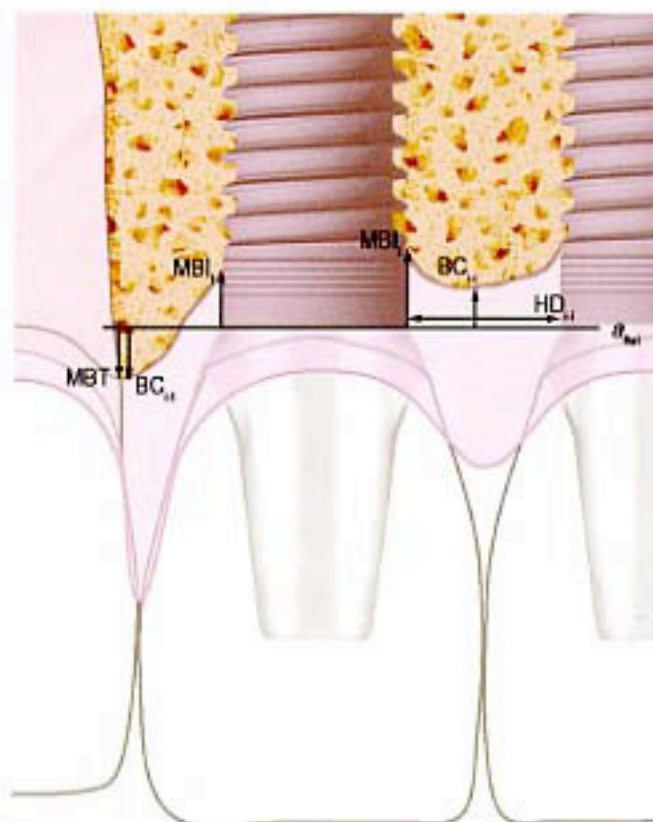


Fig. 6. Illustration of the linear measurements on radiographs in the vertical and horizontal plane.

Table 1. Characteristics of the groups at baseline

Variable	Scalloped	Flat
Number of participants	20	20
Age (years; mean/range)	38.8/18–70	35.8/18–59
Gender (male/female)	9/11	11/9
Tooth gap position ( $I_1 - I_1/I_2 - I_2/I_2 - C/C - P_1$ )	10/7/2/1	9/7/2/2
Augmentation before implant insertion (yes/no)	10/10	9/11
Local augmentation during implant insertion (yes/no)	13/7	12/8

Scalloped, scalloped implant group; Flat, flat implant group.

around scalloped implants than around flat implants. The inter-implant papilla showed compromised regeneration in both groups, with no differences between the groups. With both applied implant designs, it is difficult to establish a predictable and acceptable aesthetic result with two adjacent implant crowns in the aesthetic zone. Nevertheless, patients were very satisfied with the aesthetic outcome.

The implant survival rate for both groups was 100% following 1 year of function, which is in agreement with the common opinion on implant survival rates in the aesthetic region (Den Hartog et al. 2008). The results of this study are also comparable with the results of

articles reporting on implants with the same titanium oxide surface (TiUnite) as that used in the present study (Glauser et al. 2003, Vanden Bogaerde et al. 2005) and implants with a scalloped platform (Kan et al. 2003, Nowzari et al. 2006). A comparison with articles reporting on implant survival of adjacent implants could not be made because there were no articles reporting on survival rates.

The mean marginal bone loss around the implants during the period  $T_{post}-T_1$  was significantly higher for the scalloped implant group than that for the flat implant group. The marginal bone loss was 2.7 mm at the approximal side facing the adjacent implant and 2.6 mm

at the approximal side facing the adjacent tooth for the scalloped implant group and 0.9 mm for both approximal sides of the flat implant group. The relatively high marginal bone loss around scalloped implants resulted in a mean marginal bone level at  $T_1$  of 3.7 mm apical from the implant abutment interface at the side facing the adjacent implant and 3.3 mm apical from the microgap at the side facing the adjacent teeth. This marginal bone loss even exceeds the criteria of success stated by Albrektsson et al. (1986), proposing an average bone loss of a maximum of 1.5 mm in the first year after insertion and thereafter <0.2 mm annual bone loss. The flat implant group does meet these criteria of success. Moreover, the mean marginal bone loss of the flat implant group is comparable to the results of articles in the literature reporting on the same implant system used in single-tooth replacement (Friberg et al. 2005, 2009).

The marginal bone level around the scalloped implants seems to be less stable than the marginal bone level around flat implants. In the period between  $T_0$  and  $T_1$  (7–18 months after implant insertion), still a mean marginal bone loss of 0.5 mm at the proximal side facing the adjacent teeth and 0.4 mm at the proximal side facing the adjacent implants occurred around the scalloped implants in comparison with 0.1 mm at the proximal side facing the adjacent teeth and 0.0 mm at the proximal side facing the adjacent implant. It seems as if the marginal bone level does not follow the scalloped three-dimensional platform of the implant design, as it was meant to do. An explanation for the excessive bone loss around the scalloped implants might be that the lower lingual and facial part of the implant platform determines the marginal bone level around the implant. Furthermore, the mean inter-implant bone crest loss was higher if scalloped implants were applied. This is probably predominantly the result of two factors. At first, the higher mean marginal bone loss around the scalloped implants probably results in a larger horizontal component of the peri-implant bone loss. Secondly, the mean horizontal distance of 3.2 mm between adjacent scalloped implants was significantly smaller than the mean horizontal distance of 3.8 mm between adjacent flat implants. Moreover, there were more patients in the scalloped implant group with a horizontal distance

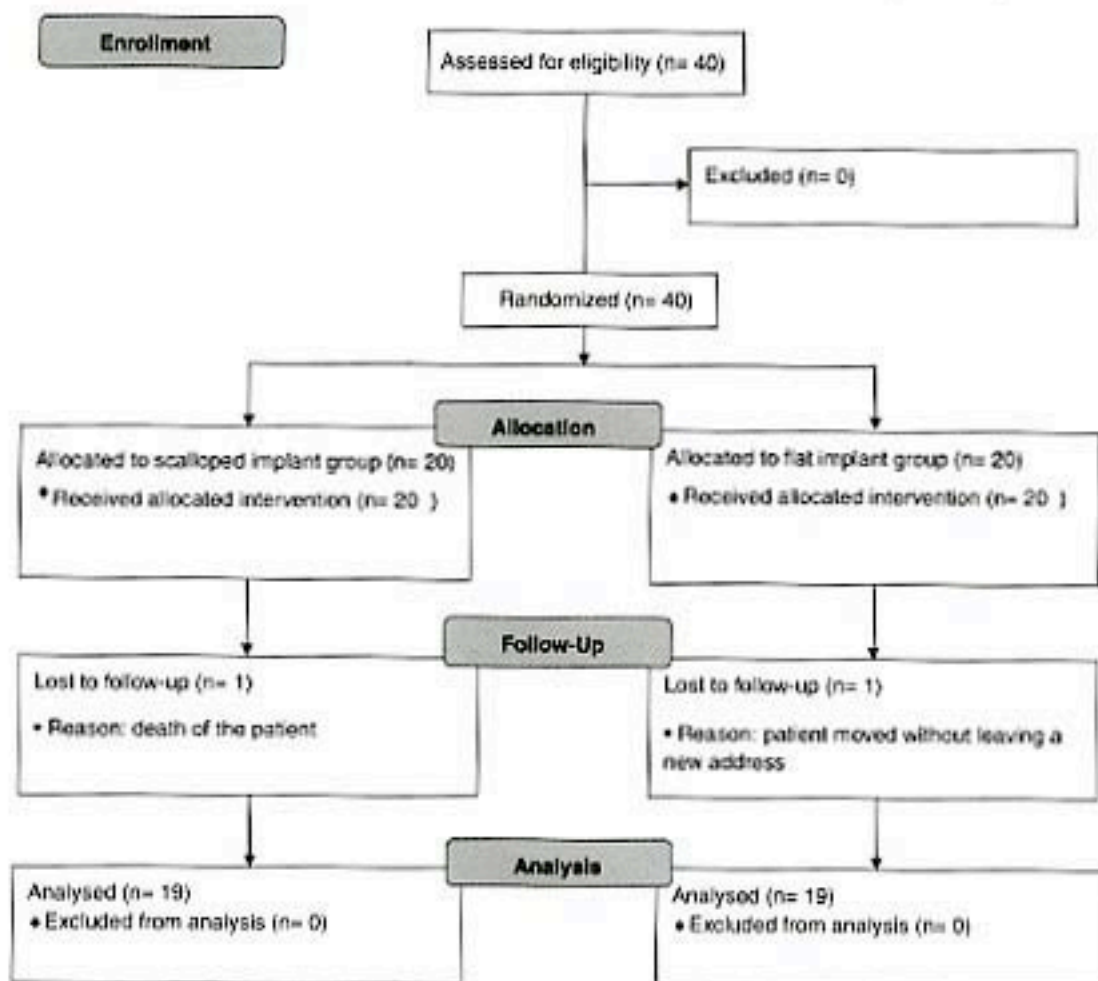


Fig. 7. Consort flow diagram.

Table 2. Mean (SD) pocket probing depth values (mm) during the evaluation period

Location		Scalloped implant group			Flat implant group			Significance*
		$T_{pre}$ (n = 20)	$T_0$ (n = 20)	$T_1$ (n = 19)	$T_{pre}$ (n = 20)	$T_0$ (n = 20)	$T_1$ (n = 19)	
Implant	Proximal side facing adjacent implant		4.4 (1.7) <sup>1</sup>	5.3 (1.5) <sup>1</sup>	3.6 (1.3)	3.8 (1.2)	$T_0: p < 0.001, T_1: p < 0.001$	
	Midbuccally		4.1 (1.3)	4.0 (1.4)	3.1 (0.9)	3.3 (0.9)	$T_0: p < 0.001, T_1: p < 0.001$	
	Proximal side facing adjacent tooth		4.7 (1.5)	4.9 (1.7)	3.4 (1.4)	3.3 (1.3)	$T_0: p = 0.003, T_1: p < 0.001$	
Tooth	Proximal side facing adjacent implant	2.1 (0.8)	2.4 (0.6)	2.4 (0.7)	2.2 (0.8)	2.2 (0.6)	2.3 (0.6)	NS
	Midbuccally	1.7 (0.6)	1.5 (0.6)	1.6 (0.8)	1.6 (0.6) <sup>2</sup>	1.3 (0.5) <sup>2,3</sup>	1.6 (0.6) <sup>2,3</sup>	NS
	Proximal side facing adjacent tooth	2.5 (0.8)	2.5 (0.6)	2.6 (0.8)	2.4 (0.6)	2.2 (0.5)	2.3 (0.6)	$T_0: p = 0.03, T_1: NS$

\*Significance for the difference between the two treatment groups.

<sup>1</sup> $p = 0.03$  for the difference in the scalloped implants group between  $T_0$  and  $T_1$ .<sup>2</sup> $p = 0.008$  for the difference in the flat implant group between  $T_{pre}$  and  $T_0$ .<sup>3</sup> $p = 0.005$  for the difference within the flat implant group between  $T_0$  and  $T_1$ . $T_{pre}$ , pre-implantation time;  $T_0$ , 1 month after the placement of the definitive crown;  $T_1$ , 12 months after the placement of the definitive crown; NS, not significant.

smaller than 3mm than in the flat implant group. This is partly due to the design of the narrow NobelPerfect platform implant, in this study placed at the position of the lateral incisor. The implant neck still has a diameter of

4.31mm instead of a diameter of 3.54mm of the narrow platform of the NobelReplace implant. An inter-implant horizontal distance smaller than 3mm will result in larger vertical reduction of the inter-implant bone crest, due to the

overlap of the resorption areas between the adjacent implant (Tarnow et al. 2000, Gastaldo et al. 2004). Given the continuing bone loss around scalloped implants, it could be that even after 18 months (short-term evaluation period), some

Table 3. Mean (SD) marginal gingiva changes (mm) measured around implants and neighbouring teeth during the evaluation period

Location	$T_{pre}-T_1^*$			$T_0-T_1^*$		
	scalloped ( <i>n</i> = 19)	flat ( <i>n</i> = 19)	difference <sup>†</sup>	scalloped ( <i>n</i> = 19)	flat ( <i>n</i> = 19)	difference <sup>†</sup>
<b>Implant</b>						
Proximal side facing adjacent implant	NA	NA		-0.3 (0.6)	0.1 (0.5)	$p = 0.001$
Midbuccally	NA	NA		-0.3 (0.5)	-0.1 (0.5)	$p = 0.02$
Proximal side facing adjacent tooth	NA	NA		0.0 (0.5)	0.1 (0.6)	NS
<b>Tooth</b>						
Proximal side facing adjacent implant	-0.4 (1.0)	-0.1 (0.6)	NS	0.1(0.5)	-0.1 (0.4)	NS
Midbuccally	-0.8 (0.7)	-0.2 (0.5)	$p < 0.001$	-0.2 (0.5)	-0.1 (0.3)	NS
Proximal side facing adjacent tooth	-0.2 (0.6)	-0.0 (0.6)	NS	-0.2 (0.4)	0.1 (0.3)	NS

\*Negative values indicate recession and positive values indicate gingiva gain.

<sup>†</sup>Significance for the difference between the two treatment groups.

$T_{pre}$ , pre-implantation time;  $T_0$ , 1 month after placement of the definitive crown;  $T_1$ , 12 months after placement of the definitive crown; Scalloped, scalloped implant group; Flat, flat implant group; NA, not applicable; NS, not significant.

Table 4. Frequency distribution of the papilla index

Score <sup>†</sup>	Scalloped implant group*				Flat implant group*			
	$T_0$		$T_1$		$T_0$		$T_1$	
	adjacent implants	implant-tooth	adjacent implants	implant-tooth	adjacent implants	implant-tooth	adjacent implants	implant-tooth
0	5	0	6	1	5	0	5	2
1	8	8	9	4	10	8	8	4
2	6	25	4	19	4	23	5	24
3	1	7	0	14	1	9	1	8
4	0	0	0	0	0	0	0	0
Total	20	40	19	38	20	40	19	38

\*No significant differences were observed between the groups.

<sup>†</sup>Score 0, no papilla formation; Score 1, less than half of the papilla is present; Score 2, at least half of the papilla is present; Score 3, papilla fills the entire approximate space; Score 4, abundance of papilla.

$T_0$ , 1 month after the placement of the definitive crown;  $T_1$ , 12 months after the placement of the definitive crown.

bone loss could still occur. An extended evaluation period is necessary to provide an insight into this phenomenon.

Papilla index scores pointed towards a compromised papilla presence. There were no significant differences between the groups. In both the groups, the inter-implant papilla scored worse compared with papillae between an implant and a natural tooth with regard to the inter-implant papilla. As the soft tissue follows the contour of the hard tissues, the reduced inter-implant bone crest height caused a compromised papilla formation. Next to the reduced bone crest height, between two adjacent implants, only a soft tissue height of 3–4 mm should be expected instead of a 5 mm soft tissue height between an implant and a tooth (Gustafson et al. 2004). Together, these two features predominantly cause the compromised papilla presence between two adjacent implants.

The mean pocket probing depths were deeper around scalloped implants than around flat implants. At  $T_1$ , the

mean pocket probing depths next to the scalloped implants ranged from 4.0 mm midbuccally to 5.3 mm at the proximal side facing the adjacent teeth, whereas around the flat implants, the mean pocket probing depths at  $T_1$  ranged from 3.3 mm midbuccally to 3.8 mm at the proximal side facing the adjacent teeth. The results of the flat implant group are comparable with the results reported on single-tooth replacements (Wennstrom et al. 2005). The studies published on scalloped implants did not report on pocket probing depth; therefore, it was not possible to compare the results of the present study with the literature. The significantly deeper peri-implant pockets around the scalloped implants are most likely the result of the more apical situated marginal bone level around the scalloped implants. The bottom of the peri-implant pockets is determined predominantly by the marginal bone level, whereas the top of the peri-implant pockets is determined by the top of the marginal gingival level. The marginal

gingiva is held up by the most coronal level of the underlying bone, which is assessed in this study as the inter-implant bone crest level between two adjacent implants and the implant-tooth bone crest level between an implant and its adjacent tooth.

The changes in the marginal gingiva level around the flat implants that occurred during the periods  $T_{pre}-T_1$  and  $T_0-T_1$  were very small, indicating that the soft tissues and their neighbouring teeth remain rather stable during the 18 months after implant insertion. These results are comparable with other studies reporting on single tooth replacement (Jemt & Lekholm 2005, Meijndert et al. 2008). During the period between  $T_0$  and  $T_1$ , marginal gingiva recessions were significantly larger around scalloped implants at the approximal side facing the adjacent implant and midbuccally in comparison with flat implants. The marginal gingiva levels around scalloped implants seem to be less stable, but changes are still relatively small. During the period between  $T_{pre}$

Table 5. Mean (SD) bone change values (mm) during the evaluation period and bone level in mm at T1

Location	Bone changes* $T_{\text{post}} - T_1$				Bone level <sup>†</sup> $T_1$			
	scalloped (n = 19)		flat (n = 19)		scalloped (n = 19)		flat (n = 19)	
	mean (SD)	difference <sup>‡</sup>	mean (SD)	difference <sup>‡</sup>	mean (SD)	difference <sup>‡</sup>	mean (SD)	difference <sup>‡</sup>
Implant								
Inter-implant bone crest	-1.8 (1.4)	$p < 0.001$	-1.0 (0.9)	$p < 0.001$	+0.2 (0.7)	$p = 0.03$	-2.1 (1.2)	$p < 0.001$
Marginal bone facing the adjacent implant	-2.7 (1.4)	$p < 0.001$	-0.9 (0.8)	$p < 0.001$	-0.4 (0.5)	$p = 0.03$	-3.7 (1.0)	$p < 0.001$
Marginal bone facing the adjacent tooth	-2.6 (1.3)	$p < 0.001$	-0.9 (0.5)	$p < 0.001$	-0.5 (0.9)	NS	-3.3 (1.1)	$p < 0.001$
Tooth								
Implant-tooth bone crest	-1.0 (1.1)	$p = 0.005$	-0.4 (1.0)	$p = 0.005$	-0.2 (0.6)	NS	-0.3 (0.9)	$p < 0.001$
Marginal bone facing the adjacent implant	-0.7 (1.1)	NS	-0.2 (0.8)	NS	+0.3 (0.7)	$p < 0.001$	+1.0 (1.1)	$p < 0.001$

\*Negative values indicate bone resorption and positive values indicate bone gain.

<sup>†</sup>Negative values indicate a level apical to the microgap and positive values indicate a level coronal to the microgap.

<sup>‡</sup>Significance for the difference between the two treatment groups.

$T_{\text{post}}$ : post-implantation time;  $T_1$ : 1 month after the placement of the definitive crown;  $T_2$ : 12 months after the placement of the definitive crown; Scalloped, scalloped implant group; Flat, flat implant group, NS, not significant.

and  $T_1$ , the loss in marginal gingiva midbuccally of the neighbouring teeth was higher in patients of the scalloped implant group than in patients of the flat implant group. No logical explanation could be provided for this difference between the groups because the implant insertion procedure did not differ between the groups.

With regard to the overall outcomes of the implant crown aesthetic index, there were no differences between the groups. The implant mucosa was rated as significantly worse when compared with the implant crown. The relatively low scores of the implant mucosa are predominantly caused by the large amount of gross deviations with regard to the position of the approximal papilla observed in both the groups. Furthermore, the position of the labial gingiva and the colour and surface of the labial mucosa showed some major and several minor deviations, also contributing to the relatively low mucosa score. The compromised papilla presence was already observed and explained with the papilla index. Moreover, in the case of adjacent missing teeth, the bone condition at the start of treatment is often compromised; due to resorption, the characteristic interdental bone peak is missing. Moreover, in both groups, in more than half of the patients, the horizontal or vertical deficiencies were to the extent that an augmentation procedure was performed before implant surgery (Table 1). As a result, the mucosa had to undergo several traumatic surgeries. The compromised situation at start and the several traumatic surgeries also might have contributed to the deviations found with regard to the position of the labial gingiva and the colour and surface of the labial mucosa. When the overall scores of the aesthetic index of this study were compared with the outcomes of a previous study reporting on single tooth replacement and also applying the aesthetic index (Meijndert et al. 2008), adjacent implant crowns yield worse aesthetic outcomes than implant crown single tooth replacements.

Patient satisfaction was very high, resulting in mean overall scores of 8.3 (range: 0–10) for the scalloped implant group and 8.6 for the flat implant group, with no differences between the groups. In accordance with the professionals' opinion, patients also rated their mucosa worse than their implant crowns. Although the professionals' opinion was very critical, patient satisfaction

Table 6. Results of the aesthetic index at T<sub>1</sub>

Deviation per item		Scalloped implant group (n = 38 implant crowns)			Flat implant group (n = 38 implant crowns)		
		no	slight	major	no	slight	major
Crown	Mesiodistal dimension	20	18	0	20	15	3
	Position of incisal edge	35	3	0	37	1	0
	Labial convexity	32	6	0	32	6	0
	Colour and translucency surface	8	30	0	17	19	2
Mucosa	Position labial margin	35	3	0	36	2	0
	Position of approximal papilla	18	13	7	21	10	7
	Contour of labial surface	0	14	24	6	16	16
	Colour and surface of labial mucosa	35	3	0	20	18	0
	6	27	5	13	22	3	
Overall score		Scalloped implant group (n = 19 patients)*			Flat implant group (n = 19 patients)*		
Overall	Poor aesthetics	13			12		
	Moderate	5			4		
	Satisfactory	1			3		
	Excellent	0			0		

\*No significant differences were observed between the groups. T<sub>1</sub>, 12 months after the placement of the definitive crown.

Table 7. Scores of the patient satisfaction questionnaire at T<sub>1</sub>

Satisfaction	Scalloped (n = 19)*	Flat (n = 19)*
Overall score <sup>†</sup>	8.3 (1.2)	8.6 (0.8)
Colour mucosa <sup>‡</sup>	2.8 (1.2)	3.0 (1.2)
Shape mucosa <sup>‡</sup>	2.4 (1.2)	2.8 (1.2)
Colour crown <sup>‡</sup>	3.5 (0.8)	3.7 (0.6)
Shape crown <sup>‡</sup>	3.2 (0.9)	3.3 (1.2)

\*Values with additives in parentheses are means with standard deviations, no significant differences were observed between the groups.

<sup>†</sup>Overall satisfaction (range: 0-10; 0 = very dissatisfied, 10 = very satisfied).

<sup>‡</sup>Satisfaction mucosa and crown (range: 0-4; 0 = very dissatisfied, 4 = very satisfied).

was very high, with an acceptable result in all cases. This difference in opinion is in agreement with earlier studies concerning single-tooth replacement (Palmer et al. 1997, Chang et al. 1999b). A reason why the patients appreciated their aesthetics could be that they were informed of the consequences and risks of implant placement before treatment and accepted the limitations of the treatment. Additionally, in comparison with the condition of their dentition before treatment, the final result was probably very satisfactory according to the patients' opinion, and factors often considered by professionals to be of significance for the aesthetic result of restorative therapy may not be of decisive importance for patient satisfaction (Chung et al. 1999a).

Long-term research is needed to assess the stability of the peri-implant hard and soft tissues of adjacent implants in the aesthetic zone. Furthermore, it would be interesting to assess

the effects of other promising implant designs such as platform switching on peri-implant tissues around adjacent implants in the aesthetic zone by means of a randomized clinical trial.

From this study, it is concluded that after 1 year of function, there was more bone loss, deeper pockets and more surrounding peri-implant mucosa recession around scalloped implants than around flat implants. With regard to papilla presence, there were no differences between patients treated with two adjacent scalloped implants or with two adjacent flat implants. With both applied implant designs, it is difficult to establish a predictable and acceptable aesthetic result, especially regarding the peri-implant mucosa, with two adjacent implant crowns in the aesthetic zone. Considering the critical opinion of the professionals, patients were very satisfied with the aesthetic outcome of the adjacent implants irrespective of the treatment concept applied.

## Acknowledgements

The investigators express their gratitude to Mr. J. de Vries (Biomedical Engineering, University Medical Center Groningen) for his valuable help in developing the software for the radiographic measurements. This study has been supported by Nobel Biocare (grant no. 2004-288).

## References

- Abreksson, T., Zarb, G., Worthington, P. & Eriksson, A. R. (1986) The long-term efficacy of currently used dental implants: a review and proposed criteria of success. *International Journal of Oral and Maxillofacial Implants* **1**, 11-25.
- Altman, D. G. (1991) *Practical statistics for medical research*. London: Chapman & Hall.
- Chung, M., Odman, P. A., Weststrom, J. L. & Anderson, B. (1999a) Esthetic outcome of implant-supported single-tooth replacements assessed by the patient and by prosthodontists. *International Journal of Prosthodontics* **12**, 335-341.
- Chung, M., Weststrom, J. L., Odman, P. & Anderson, B. (1999b) Implant supported single-tooth replacements compared to contralateral natural teeth. Crown and soft tissue dimensions. *Clinical Oral Implants Research* **10**, 185-194.
- Choquet, V., Hermans, M., Adrianienssens, P., Doelmann, P., Tunnou, D. P. & Malvez, C. (2001) Clinical and radiographic evaluation of the papilla level adjacent to single-tooth dental implants. A retrospective study in the maxillary anterior region. *Journal of Periodontology* **72**, 1364-1371.
- Den Hartog, L., Slater, J. J., Vissink, A., Meijer, H. J. & Raghoobar, G. M. (2008) Treatment outcome of immediate, early and conventional single-tooth implants in the aesthetic zone: a systematic review to survival, bone level, soft-tissue, aesthetics and patient satisfaction. *Journal of Clinical Periodontology* **35**, 1073-1086.

- Foell, F., Eufelder, E., Buchner, A. & Lang, A. G. (2009) Statistical power analyses using G\*Power 3.1: tests for correlation and regression analyses. *Behavior Research Methods* **41**, 1149–1160.
- Fischer, K., Backstrom, M. & Sennethy, L. (2009) Immediate and early loading of oxidized tapered implants in the partially edentulous maxilla: a 1-year prospective clinical, radiographic, and resonance frequency analysis study. *Clinical Implant Dentistry and Related Research* **11**, 69–80.
- Friberg, B., Dahlöf, C., Widmark, G., Östman, P. O. & Billström, C. (2005) One-year results of a prospective multicenter study on Brånemark System implants with a TiUnit surface. *Clinical Implant Dentistry and Related Research* **7** (Suppl. 1), S70–S75.
- Gastaldo, J. F., Cury, P. R. & Sendyk, W. R. (2004) Effect of the vertical and horizontal distances between adjacent implants and between a tooth and an implant on the incidence of interproximal papilla. *Journal of Periodontology* **75**, 1242–1246.
- Glasser, R., Lindgren, A. K., Gorkow, J., Sennethy, L., Postmann, M., Rahstaller, P. & Hammerle, C. H. (2003) Immediate occlusal loading of Brånemark TiUnit implants placed predominantly in soft bone: 1-year results of a prospective clinical study. *Clinical Implant Dentistry and Related Research* **5** (Suppl. 1), 47–56.
- Grander, U. (2000) Stability of the mucosal topography around single-tooth implants and adjacent teeth: 1-year results. *International Journal of Periodontics and Restorative Dentistry* **20**, 11–17.
- Jemt, T. (1997) Regeneration of gingival papillae after single-implant treatment. *International Journal of Periodontics and Restorative Dentistry* **17**, 326–333.
- Jemt, T. & Lekholm, U. (2005) Single implants and buccal bone grafts in the anterior maxilla: measurements of buccal crestal contours in a 6-year prospective clinical study. *Clinical Implant Dentistry and Related Research* **7**, 127–135.
- Kan, J. Y., Hungcharassang, K., Liddlelow, G., Henry, P. & Goodacre, C. J. (2007) Periimplant tissue response following immediate provisional restoration of scalloped implants in the esthetic zone: a one-year pilot prospective multicenter study. *Journal of Prosthetic Dentistry* **97**, S109–S118.
- Kan, J. Y., Rangcharassang, K., Umeta, K. & Kois, J. C. (2003) Dimensions of peri-implant mucosa: an evaluation of maxillary anterior single implants in humans. *Journal of Periodontology* **74**, 557–562.
- Kourkous, S., Dedi, K. D., Pagotte, D. W. & Mol, A. (2009) Interproximal tissue dimensions in relation to adjacent implants in the anterior maxilla: clinical observations and patient aesthetic evaluation. *Clinical Oral Implants Research* **20**, 1375–1385.
- Levi, A., Peter, W. J., Agar, J. R., Reisine, S. T. & Taylor, T. D. (2005) Patient self-reported satisfaction with maxillary anterior dental implant treatment. *International Journal of Oral and Maxillofacial Implants* **18**, 113–120.
- McAllister, B. S. (2007) Scalloped implant design enhance interproximal bone levels. *International Journal of Periodontics and Restorative Dentistry* **27**, 9–15.
- Meijer, H. J., Stellingsma, K., Meijndert, L. & Raghoobar, G. M. (2005) A new index for rating aesthetics of implant-supported single crowns and adjacent soft tissues—the Implant Crown Aesthetic Index. *Clinical Oral Implants Research* **16**, 645–649.
- Meijndert, L., Meijer, H. J., Raghoobar, G. M. & Vissink, A. (2004) A technique for standardized evaluation of soft and hard peri-implant tissues in partially edentulous patients. *Journal of Periodontology* **75**, 646–651.
- Meijndert, L., Meijer, H. J., Stellingma, K., Stegenga, B. & Raghoobar, G. M. (2007a) Evaluation of aesthetics of implant-supported single tooth replacements using different bone augmentation procedures: a prospective randomized clinical study. *Clinical Oral Implants Research* **18**, 715–719.
- Meijndert, L., Raghoobar, G. M., Meijer, H. J. & Vissink, A. (2008) Clinical and radiographic characteristics of single-tooth replacements preceded by local ridge augmentation: a prospective randomized clinical trial. *Clinical Oral Implants Research* **19**, 1295–1303.
- Nojken, R., Morbach, T., Kunkel, M. & Wagner, W. (2007) Immediate function with NobelPerfect implants in the anterior dental arch. *International Journal of Periodontics and Restorative Dentistry* **27**, 277–285.
- Nowzari, H., Chee, W., Yi, K., Pak, M., Chung, W. H. & Rich, S. (2006) Scalloped dental implants: a retrospective analysis of radiographic and clinical outcomes of 37 NobelPerfect implants in 6 patients. *Clinical Implant Dentistry and Related Research* **8**, 1–10.
- Palmer, R. M., Farkondeh, N., Palmer, P. I. & Wilson, R. F. (2007) Astra Tech single-tooth implants: an audit of patient satisfaction and soft tissue form. *Journal of Clinical Periodontology* **34**, 633–638.
- Palmer, R. M., Smith, B. J., Palmer, P. I. & Floyd, P. D. (1997) A prospective study of Astra single tooth implants. *Clinical Oral Implants Research* **8**, 173–179.
- Sewerin, I. P. (1990) Errors in radiographic assessment of marginal bone height around osseointegrated implants. *Scandinavian Journal of Dental Research* **98**, 428–433.
- Tarrow, D. P., Cho, S. C. & Wallace, S. S. (2000) The effect of inter-implant distance on the height of inter-implant bone crest. *Journal of Periodontology* **71**, 546–549.
- Varden Høegsø, L., Ringert, B. & Wendelhag, I. (2005) Immediate/early function of Brånemark System TiUnit implants in fresh extraction sockets in maxilla and posterior mandibles: an 18-month prospective clinical study. *Clinical Implant Dentistry and Related Research* **7** (Suppl. 1), S121–S130.
- Vernyker, K., Collaert, B., Linders, U., Bjorn, A. L. & de Bruyn, H. (2003) Patient satisfaction and quality of single-tooth restorations. *Clinical Oral Implants Research* **14**, 119–124.
- Weinstamm, J. L., Ekstrøm, A., Grondahl, K., Karlsson, S. & Lindhe, J. (2005) Implant-supported single-tooth restorations: a 5-year prospective study. *Journal of Clinical Periodontology* **32**, 567–574.
- Wehrle, P. S. (2005) Nobel Perfect esthetic scalloped implant: rationale for a new design. *Clinical Implant Dentistry and Related Research* **7** (Suppl. 1), 64–73.

## Address:

Henny J. A. Meijer  
Department of Oral and Maxillofacial Surgery  
University Medical Center Groningen  
PO Box 30.001  
NL-9700 RB Groningen  
The Netherlands  
E-mail: h.j.a.meijer@kchir.umcg.nl

## Clinical relevance

**Scientific rationale for the study:** Dental implants are widely used to replace missing anterior teeth. In an attempt to preserve the peri-implant hard and soft tissues and thereby make implant therapy in the aesthetic zone more predictable, several new implant designs were launched in

recent years. One of these solutions is the scalloped implant, which was designed to keep or create the interproximal bony peaks that support the overlying soft tissues and thereby aiming for a preservation or the creation of papillae.

**Principal findings:** After 1 year of function, there was more bone loss

around scalloped implants than around flat implants. There was no significant difference between the groups with regard of the papilla index and patients' satisfaction.

**Practical implications:** Scalloped implants do not meet the desired goal of keeping or creating interproximal bone levels.