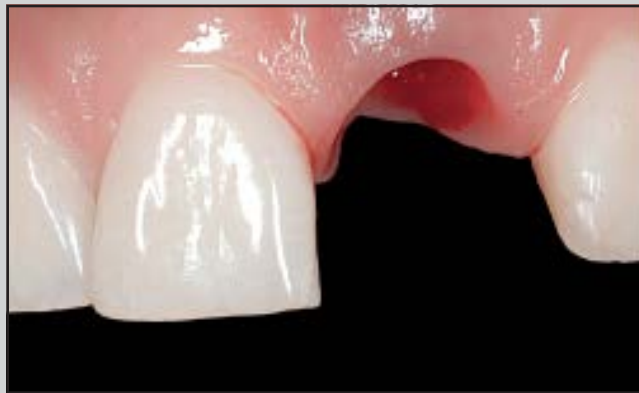

Emergence Profile Design Based on Implant Position in the Esthetic Zone



Marius Steigmann, DDS^{1,2}
 Alberto Monje, DDS³
 Hsun-Liang Chan, DDS, MS⁴
 Hom-Lay Wang, DDS, MS, PhD⁵

One of the most challenging tasks in implant dentistry is to fulfill the esthetic expectations of patients. While implant positioning and adequate amounts of soft and hard tissues are essential for achieving an esthetic outcome, the emergence profile of an abutment/restoration also plays an important role in the definitive appearance of implant prostheses. Therefore, the purpose of this paper is to propose a clinical guideline for designing an abutment/prosthesis based on implant position. By customizing the emergence profile, the overlying soft tissues could be properly contoured and maintained, and pleasing implant prostheses could be achieved. (Int J Periodontics Restorative Dent 2014;34:559–563. doi: 10.11607/prd.2016)

Implant dentistry has evolved to a stage where osseointegration of the implant fixture to bone is no longer a concern. However, achieving optimal implant esthetics to fulfill a patient's expectations remains a challenge. This is primarily due to the fact that a significant amount of hard and soft tissue loss may occur after the tooth is removed.¹ Also, there are inherent differences in the attachment to the surrounding bone and soft tissues for an implant as compared with a tooth.² As such the reconstruction of an esthetic implant restoration requires greater clinical and technical skills. An esthetic implant restoration should be harmonious with the patient's facial appearance and the rest of his or her dentition.³ The margin, color, and contour of the peri-implant mucosa should be symmetric with that of the contralateral teeth and/or implants, and the papilla should fill the interproximal space.^{4–6} The shade, contour, and proportion of the implant restoration should be optimal⁶; and most importantly, the implant restoration must have a pleasing appearance that is acceptable to the patient.

¹Private Practice, Neckargemünd, Germany.

²Adjunct Clinical Associate Professor, Graduate Periodontics, Department of Periodontics and Oral Medicine, University of Michigan School of Dentistry, Ann Arbor, Michigan, USA.

³Resident, Graduate Periodontics, Department of Periodontics and Oral Medicine, University of Michigan School of Dentistry, Ann Arbor, Michigan, USA.

⁴Clinical Assistant Professor, Graduate Periodontics, Department of Periodontics and Oral Medicine, University of Michigan School of Dentistry, Ann Arbor, Michigan, USA.

⁵Professor and Director of Graduate Periodontics, Graduate Periodontics, Department of Periodontics and Oral Medicine, University of Michigan School of Dentistry, Ann Arbor, Michigan, USA.

Correspondence to: Dr Hom-Lay Wang, Department of Periodontics and Oral Medicine, University of Michigan School of Dentistry, 1011 North University Avenue, Ann Arbor, MI 48109-1078, USA; fax: 734-936-0374; email: homlay@umich.edu.

©2014 by Quintessence Publishing Co Inc.

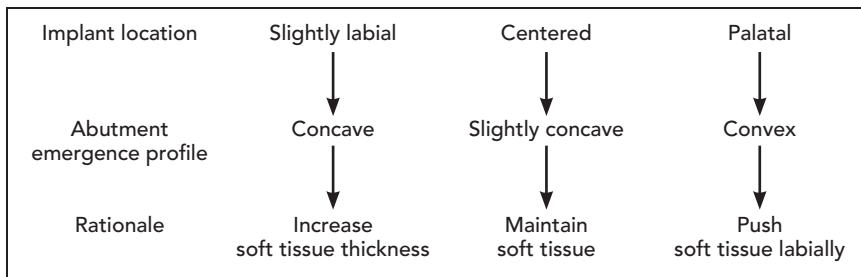


Fig 1 Decision tree for achieving a harmonious emergence profile based on labiopalatal implant position.

Discrepancies between the soft tissue margins of implant restorations and teeth are most obvious to the patient and hence should be avoided. The level of the mucosal margin is determined by many factors, such as thickness of underlying bone,^{7,8} mucosa thickness,² implant position,^{9,10} and the contour of the abutment and/or prosthesis.^{11,12} It has been suggested that alveolar bone crest thickness of at least 2.0 mm is required for a stable mucosal margin.¹³ Thick mucosa is thought to be able to better resist soft tissue recession; thus the underlying bone volume can be maintained.² Conversely, a thin tissue biotype usually has a scalloped appearance and responds to mechanical insults and inflammation with recession.¹⁴ It is undeniable that ideal implant position is a prerequisite for a pleasing mucosal margin level.¹⁵ Ideal implant position includes its placement in the apicocoronal, mesiodistal, and labiopalatal directions. A frequently forgotten dimension is the axis of the implant, which can also influence the stability of the peri-implant mucosal levels.^{16,17} Implants that are malpositioned, especially those that are placed too labially, can

create significant esthetic complications.¹⁸ Minor mismatches in implant positioning due to ridge morphology and lack of surgical skills may be compensated for by abutment designs.¹⁹ Therefore, the aim of this article is to demonstrate with clinical cases how an abutment might be constructed based on the implant position to optimize esthetics.

Decision Tree

Figure 1 presents a decision tree proposed as a guide for selecting the proper shape of an abutment based on implant positioning. The significance of the implant position is its labiopalatal orientation in relation to the alveolar bone and adjacent teeth. The decision tree is not intended for an implant that is placed beyond an acceptable limit (eg, outside the bony housing).

Clinical scenarios

Centrally placed implants

In this article, a centrally placed implant is defined as one where the labial aspect of the implant plat-

form is approximately 2 mm palatal to an imaginary line connecting the most prominent facial contours of the adjacent crowns (ie, the buccal flange).²⁰ The emergence profile of such implants should be slightly undercontoured so the soft tissues can be properly supported without undue tension (Fig 2). In order to achieve an esthetic restoration, the emergence profile of the abutment should be 0.5 to 1.0 mm palatal to that of the adjacent teeth at the mucosal margin. The provisional restoration is a good tool for sculpting the peri-implant soft tissues prior to placement of the definitive restoration. Its emergence profile can easily be modified so that the peri-implant soft tissues can be contoured to a desirable profile. The definitive restoration can thus be fabricated based on the contour of the provisional restoration, thereby achieving a congruent and esthetic restorative outcome.

Palatally placed implants

When an implant is placed more palatally (> 2 mm from the buccal bone flange), a convex emergence profile, which will push the tissues labially, may be required to obtain a harmonious scallop. In Fig 3, the facial contour of the abutment was exaggerated to provide adequate tissue support. Slight blanching of the mucosa should be observed immediately after the abutment is placed. This indicates that there is positive pressure exerting from the abutment to the peri-implant soft tissues. Within minutes, the

Fig 2 A centrally located implant replacing the maxillary left central incisor.

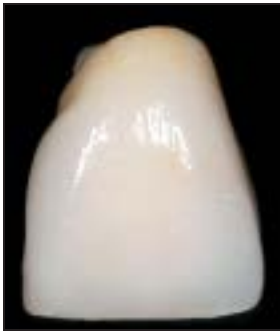
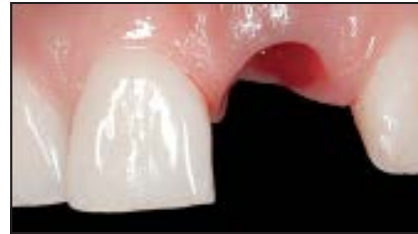
Fig 2a (left) The emergence profile is slightly concave so as to maintain the soft tissue volume.



Figs 2b and 2c (below) Proper tissue support is achieved with the restoration.

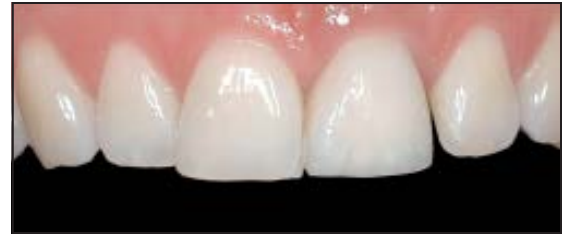

Fig 3 A palatally placed implant replacing the maxillary left central incisor.

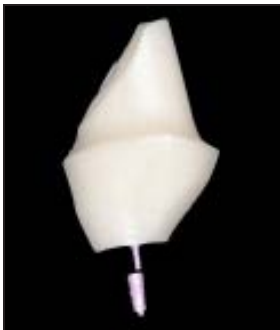

Fig 3a The emergence profile was designed to create a pronounced convex contour.

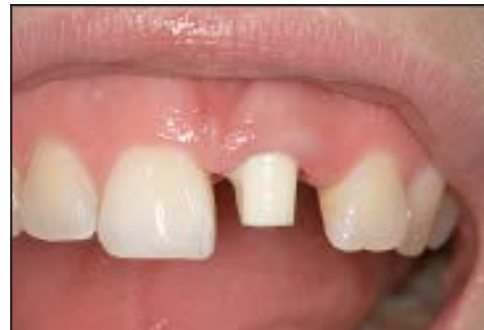

Fig 3b The soft tissues have been moved labially.

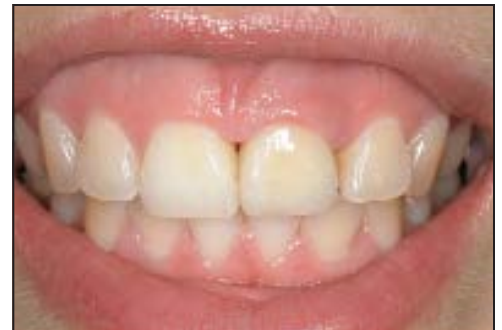

Fig 3c A pleasing outcome was achieved after implant restoration.

tissues will reequilibrate, and the normal pink coloration of the tissues will return. If the facial contour is not properly supported, a grayish hue will surface through the soft tissues under natural light. Therefore, it is recommended that the patient be brought under natural light to better evaluate the esthetics of the implant restoration prior to cementation.

Labially placed implants

An undercontoured abutment may be used to restore an implant that

is within the buccal bone housing but slightly labially positioned. This abutment would exert minimal pressure on the facial soft tissues and may allow for an increase in soft tissue volume. The degree of concavity designed on the abutment is dependent on the labial position of the implant. In Fig 4, the discrepancy between the contour of the abutment and crown was to promote soft tissue growth. The cervical part of the crown was also slightly undercontoured relative to the adjacent natural teeth to further reduce the pressure exerted on the soft tissues.

Discussion

To achieve an esthetic outcome, every detail has to be considered at various stages of implant treatment. At the planning stage, patients with a higher risk for esthetic complications should be identified. High smile line, thin tissue biotype, scalloped gingival profile, and unrealistic patient expectations indicate that the risk for an unsatisfactory esthetic outcome is high.⁴ A thick tissue biotype is more resistant to recession^{21,22} and better masks the color of titanium.²³ Thin tissue and a long papilla tend to recede more

Fig 4 A slightly labially located implant replacing the maxillary right central incisor.

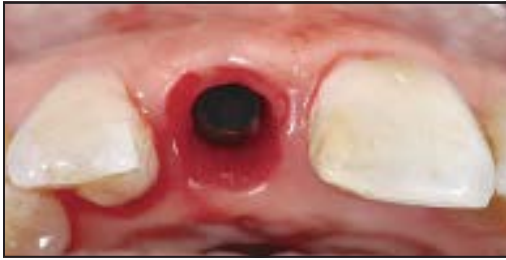

Fig 4a (left) Occlusal view showing the slightly labial positioning of the implant.

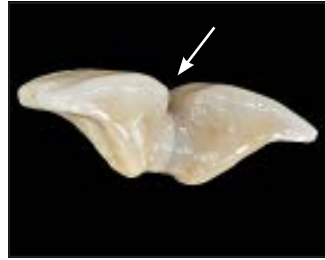
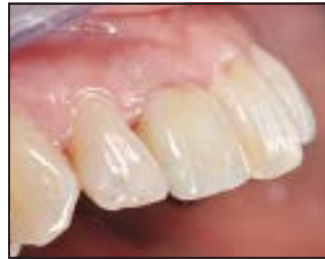
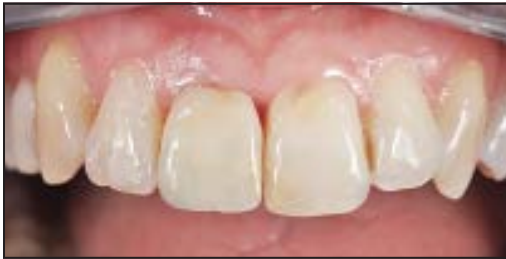Fig 4b (right) The achievement of an optimal emergence profile relies on creation of a concave contour (arrow).



Figs 4c and 4d The abutment design reduces pressure on the soft tissues, thus achieving an esthetic outcome.

after surgical procedures, resulting in unesthetic outcomes.²⁴ In addition, selecting the right surgical technique to minimize tissue trauma is crucial for those patients. Procedures that may preserve soft and hard tissues around an implant, such as flapless surgery,²⁵ the papilla preservation technique,²⁶ and an esthetic buccal flap design,²⁷ should be considered. More importantly, implants have to be placed in a prosthetically acceptable position.²⁰ Negligence of the above-mentioned procedures may lead to esthetic failures.

At the prosthetic stage, the clinician can use a properly contoured abutment to mold the soft

tissues for a better esthetic profile when it is not possible to place the implant in an ideal position due to anatomical or skill limitations.^{17,28} The connective tissue is the main component of peri-implant mucosa. It is primarily made up of dense type I collagen fibers that are less vascular and parallel to the long axis of the implant.²⁹ Therefore, the abutment acts to support the mucosa. Optimal pressure from the abutment is required to maintain the contour and shape of the mucosa. Less pressure can lead to undersupported mucosa, resulting in a flat soft tissue profile, while excessive pressure risks midfacial mucosal recession.³⁰

Based on the proposed decision tree, the contour of an abutment should be chosen based on the implant position. For an ideally placed implant, a slightly concave abutment is indicated. In cases with a slight mismatch in implant positioning, an over- or undercontoured abutment should be considered. The emergence profile of an implant that is labially located should be concave to allow for an increase in soft tissue thickness.⁴ In contrast, if an implant is located slightly palatally,^{20,31,32} a convex abutment is indicated to move the soft tissue labially. The guidelines only apply to situations in which the implant is placed in an acceptable location. If the implant is placed beyond the acceptable limit, it may be wise to reposition the implant if primary stability is not compromised or abort the placement and perform bone augmentation.

Conclusions

The emergence profile of implant-supported restorations plays an important role in achieving esthetics. Understanding the concepts and decision tree described in this article will help clinicians design a properly shaped abutment and restoration for optimal tissue support and eventually an esthetically pleasing implant restoration.

Acknowledgments

The authors reported no conflicts of interest related to this study.

References

1. Schropp L, Kostopoulos L, Wenzel A. Bone healing following immediate versus delayed placement of titanium implants into extraction sockets: A prospective clinical study. *Int J Oral Maxillofac Implants* 2003;18:189–199.
2. Fu JH, Lee A, Wang HL. Influence of tissue biotype on implant esthetics. *Int J Oral Maxillofac Implants* 2011;26:499–508.
3. Okuda WH. Creating facial harmony with cosmetic dentistry. *Curr Opin Cosmet Dent* 1997;4:69–75.
4. Chu SJ, Paravina RD. Periodontal-prosthodontics in contemporary practice. *J Dent* 2013;41(suppl 3):e1–e2.
5. Chu SJ, Tarnow DP, Tan JH, Stappert CF. Papilla proportions in the maxillary anterior dentition. *Int J Periodontics Restorative Dent* 2009;29:385–393.
6. Chu SJ, Tan JH, Stappert CF, Tarnow DP. Gingival zenith positions and levels of the maxillary anterior dentition. *J Esthet Restor Dent* 2009;21:113–120.
7. Fu JH, Yeh CY, Chan HL, Tatarakis N, Leong DJ, Wang HL. Tissue biotype and its relation to the underlying bone morphology. *J Periodontol* 2010;81:569–574.
8. La Rocca AP, Alemany AS, Levi P Jr, Juan MV, Molina JN, Weisgold AS. Anterior maxillary and mandibular biotype: Relationship between gingival thickness and width with respect to underlying bone thickness. *Implant Dent* 2012;21:507–515.
9. Reikie DF. Esthetic and functional considerations for implant restoration of the partially edentulous patient. *J Prosthet Dent* 1993;70:433–437.
10. Smukler H, Castellucci F, Capri D. The role of the implant housing in obtaining aesthetics: Generation of peri-implant gingivae and papillae—Part 1. *Pract Proced Aesthet Dent* 2003;15:141–149.
11. Chee WW, Donovan TE. Treatment planning and soft tissue management for optimal implant aesthetics. *Ann Acad Med Singapore* 1995;24:113–117.
12. Mazurat RD, Love WB, Pesun IJ. The role of the restorative dentist in the diagnosis and maintenance phases of implant therapy—Part II: Prosthetic planning. *J Can Dent Assoc* 1994;60:814–818.
13. Grunder U, Gracis S, Capelli M. Influence of the 3-D bone-to-implant relationship on esthetics. *Int J Periodontics Restorative Dent* 2005;25:113–119.
14. Kan JY, Rungcharassaeng K, Umezu K, Kois JC. Dimensions of peri-implant mucosa: An evaluation of maxillary anterior single implants in humans. *J Periodontol* 2003;74:557–562.
15. Zucchelli G, Mazzotti C, Mounssif I, Mele M, Stefanini M, Montebugnoli L. A novel surgical-prosthetic approach for soft tissue dehiscence coverage around single implant. *Clin Oral Implants Res* 2013;24:957–962.
16. Lin GH, Chan HL, Wang HL. Effects of currently available surgical and restorative interventions on reducing midfacial mucosal recession of immediately placed single-tooth implants: A systematic review. *J Periodontol* 2014;85:92–102.
17. Chan HL, Garaicoa-Pazmino C, Suarez F, et al. Incidence of implant buccal plate fenestration in the esthetic zone: A cone beam computed tomography study. *Int J Oral Maxillofac Implants* 2014;29:171–177.
18. Evans CD, Chen ST. Esthetic outcomes of immediate implant placements. *Clin Oral Implants Res* 2008;19:73–80.
19. Su H, Gonzalez-Martin O, Weisgold A, Lee E. Considerations of implant abutment and crown contour: Critical contour and subcritical contour. *Int J Periodontics Restorative Dent* 2010;30:335–343.
20. Buser D, Martin W, Belser UC. Optimizing esthetics for implant restorations in the anterior maxilla: Anatomic and surgical considerations. *Int J Oral Maxillofac Implants* 2004;19(suppl):43–61.
21. Small PN, Tarnow DP, Cho SC. Gingival recession around wide-diameter versus standard-diameter implants: A 3- to 5-year longitudinal prospective study. *Pract Proced Aesthet Dent* 2001;13:143–146.
22. Kao RT, Fagan MC, Conte GJ. Thick vs. thin gingival biotypes: A key determinant in treatment planning for dental implants. *J Calif Dent Assoc* 2008;36:193–198.
23. Jung RE, Sailer I, Hammerle CH, Attin T, Schmidlin P. In vitro color changes of soft tissues caused by restorative materials. *Int J Periodontics Restorative Dent* 2007;27:251–257.
24. Steigmann M. Aesthetic flap design for correction of buccal fenestration defects. *Pract Proced Aesthet Dent* 2008;20:487–493.
25. Kan JY, Rungcharassaeng K, Ojano M, Goodacre CJ. Flapless anterior implant surgery: A surgical and prosthodontic rationale. *Pract Periodontics Aesthet Dent* 2000;12:467–474.
26. Novaes AB Jr, Barros RR, Muglia VA, Borges GJ. Influence of interimplant distances and placement depth on papilla formation and crestal resorption: A clinical and radiographic study in dogs. *J Oral Implantol* 2009;35:18–27.
27. Steigmann M, Wang HL. Esthetic buccal flap for correction of buccal fenestration defects during flapless immediate implant surgery. *J Periodontol* 2006;77:517–522.
28. Koticha T, Fu JH, Chan HL, Wang HL. Influence of thread design on implant positioning in immediate implant placement. *J Periodontol* 2012;83:1420–1424.
29. Berglundh T, Abrahamsson I, Welander M, Lang NP, Lindhe J. Morphogenesis of the peri-implant mucosa: An experimental study in dogs. *Clin Oral Implants Res* 2007;18:1–8.
30. Bishti S, Strub JR, Att W. Effect of the implant-abutment interface on peri-implant tissues: A systematic review. *Acta Odontol Scand* 2014;72:13–25.
31. Lin GH, Chan HL, Wang HL. The effect of currently available surgical and restorative interventions on reducing midfacial mucosal recession of immediately placed single-tooth implants: A systematic review. *J Periodontol* 2014;85:92–102.
32. Morton D, Chen ST, Martin WC, Levine RA, Buser D. Consensus statements and recommended clinical procedures regarding optimizing esthetic outcomes in implant dentistry. *Int J Oral Maxillofac Implants* 2014;29(suppl):216–220.

Copyright of International Journal of Periodontics & Restorative Dentistry is the property of Quintessence Publishing Company Inc. and its content may not be copied or emailed to multiple sites or posted to a listserv without the copyright holder's express written permission. However, users may print, download, or email articles for individual use.